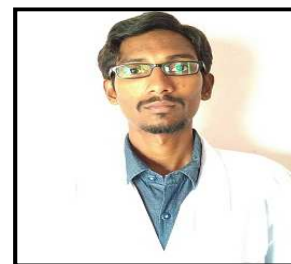




Asian Journal of Research in Pharmaceutical Sciences and Biotechnology

Journal home page: www.ajrpsb.com



TRIPLE INFECTION OF DENGUE, MALARIA AND TYPHOID: A RARE CASE REPORT IN PEDIATRICS

Shaik Ali Basha^{*1}, B. Sathiswara¹, R. Siddarama²

¹Pharm D Student, Department of Pharmacy Practice, Creative Educational Society's College of Pharmacy, N.H. 4, Chinnatekur, Kurnool, Andhra Pradesh, India.

²Department of Pharmacy Practice, Creative Educational Society's College of Pharmacy, N.H. 4, Chinnatekur, Kurnool, Andhra Pradesh, India.

ABSTRACT

Dengue, malaria and typhoid are endemic in southern part of India representing a major health problems. Co-infections of dengue with malaria, other bacterial or viral infections has been described in many parts of the world. However there are only two cases of triple infection in adults reported anywhere in literature to our knowledge. We report a rare case of triple infection in 4 yr old female child.

A 4 yr old female child was admitted in the hospital with chief complaints of fever associated with chills, abdominal discomfort. Outside reports shown positive for malaria, typhoid at 1:80 dilutions and also shown positive for Ig M and Ig G antibodies in dengue serology suggesting it as a case of triple infection. She was started with intravenous artesunate, amikacin, cefoperazone + sulbactam, along with the symptomatic treatment. Good prognosis was observed to the treatment and was discharged after the normalisation of the condition.

KEYWORDS

Dengue, Malaria, Typhoid and Triple infection.

Author for Correspondence:

Shaik Ali Basha,
Pharm D student,
Creative Educational Society's College of Pharmacy,
N.H. 4, Chinnatekur, Kurnool,
Andhra Pradesh, India.

Email: alibasha65@gmail.com

INTRODUCTION

Malaria and typhoid are common causes of fever in many parts of Andhra Pradesh especially Rayalaseema. Severe cases of dengue were reported that lead to death in the past years. Co-infection of dengue with typhoid and malaria with dengue was reported in literature worldwide^{1,2}, but triple infection having dengue, malaria, typhoid in the same patient has been described in only two cases to our knowledge. However these two reported cases were in adults and no case of triple infection was reported in paediatrics. We report a case of triple infection with dengue, malaria and typhoid in

a 4 yr old female child. This is the first case of triple infection to be reported in pediatric population.

CASE REPORT

A 4 yr old female child from a nearby village came to the hospital with chief complaints of fever since one week which is associated with chills, abdominal discomfort. Outside reports shown positive for malarial parasite, widal test positive for typhi 'O' at 1:60 dilutions and for typhi 'H' at 1:80 dilutions, dengue serology shown weakly positive for both the antibodies Ig M and Ig G, elevated CRP levels (40.3 mg/dl) and with normal bilirubin levels. She was admitted as a case of triple infection i.e., dengue, malaria with typhoid. She is a known case of febrile seizures and also with bronchial asthma.

On examination her vitals were stable. She was conscious and coherent with pallor changes. Lungs were clear and there was no cardiac murmur. There was a palpable spleen four cms below the left costal margin and abdomen was slightly tender.

A repeat widal test shown positive at 1:40 dilutions and also positive for malarial parasite by kit method. Haemoglobin was decreased to 8.7g/dl (11.5-16.5g/dl) and platelets were decreased to 8000 cells/cumm (1.5-4 lakh cells/cumm). CRP levels were increased to 16mg/dl (0-6 mg/dl) and normal random blood sugar with 86mg/dl. Serum electrolytes were normal showing sodium- 143 mmol/l, potassium- 3.6 mmol/l, chlorides- 99mmol/l and calcium- 8.6 mg/dl. Liver function tests were normal i.e., total bilirubin, direct bilirubin, indirect bilirubin, SGOT, SGPT. Viral screening revealed non reactive and also negative for HbsAg, HCV. Ultrasound abdomen shows mild hepatomegaly and oedematous gall bladder suggesting viral hemorrhagic fever.

The patient was started on Inj Artesunate 60mg twice daily, Inj Cefoperazone + sulbactam (1000mg+500mg) twice daily, Inj Amikacin 200mg two times a day, Inj Rabeprazole 20mg twice a day, Tab Paracetamol 250mg 6th hourly, Syp Carica papaya leaf extract 5ml thrice daily along with fresh whole blood and single donor platelets transfusion. She started showing gradual response from day three after admission and by day 7 she was afebrile, decreased abdominal discomfort and her platelets

were normal. She was discharged from the hospital on the 7th day and suggested to review after a week. At follow up after a week she had no complaints and was normal.

DISCUSSION

Dengue, malaria and typhoid are endemic in southern part of India representing a major health problem. Co-infections of dengue with malaria³⁻⁵ and malaria with enteric fever² have been reported in the past days and these infections are common among the people in these regions. The etiology of these infections were known clearly and steps should be taken so as to prevent these infections. In our case report, we observed the triple infection by dengue, malaria and typhoid. These cases of triple infection are unusual unlike the concurrent infections.

Dengue fever is caused by dengue virus which is a single stranded RNA belonging to the family *flaviviridae* and genus *flavivirus*. The four serotypes of dengue virus are DENV1, DENV2, DENV3, DENV4. This infection is principally transmitted by the arthropods especially *Aedes aegypti*⁶. Due to the mosquito burden in monsoon and post monsoon period, dengue fever is predominant during this period. The main risk factors include poor or lack of sanitation, ineffective mosquito control, population growth, deforestation, urbanisation⁷ etc., Dengue fever can result in increased susceptibility to secondary infections mainly during the convalescence period.

Malaria is caused by the malarial parasite Plasmodium, most commonly by *P.falciparum*, *P.vivax*, *P.malariae* and rarely by *P.ovale* which is more common in West Africa⁸. It is mainly transmitted by the mosquito which carries the infection from infected to the normal person. Typhoid fever or enteric fever is caused by the *Salmonella enterica* sub species *enterica* serotype *typhi*. Humans are the only reservoir and host for typhoid fever. Typhoid is transmitted by faecal contamination of water and food in endemic areas especially by carriers handling food⁹.

Supportive treatment is sufficient for dengue fever by monitoring the complications which is a must step. Supportive treatment include paracetamol to

treat high grade fever, intravenous fluids to prevent dehydration, ORS sachets to maintain electrolyte balance, carica papaya leaf extract based tablets or syrups which acts as an adjunct to improve platelet count. Thrombocytopenia, the main condition observed should be corrected preferably with single donor platelets (SDP) if there is a systemic bleeding or if the platelets are below 20000 to 30000 cells/cumm and when there is no systemic bleeding, platelet count >30000 cells/cumm but less than the normal count then platelet rich plasma (PRP) or fresh whole blood be preferred for transfusion¹⁰. On the other hand malaria caused by severe *P.falciparum* should be treated with artemesin based combination therapy as delayed treatment substantially increase the mortality¹¹. Selected antibiotics should be preferred to treat typhoid infection based on the antibiotic susceptibility testing.

CONCLUSION

Patients diagnosed with dengue fever can have poor immunity during convalescent period which makes them susceptible to other infections especially in the monsoon and post monsoon season. Elevation of symptoms of fever despite the treatment, poor prognosis suggest to look for the other possible co-infections especially malaria and typhoid. Suspecting and early diagnosing a triple infection can result in preventing morbidity and mortality resulting in raising the standards of living. However dengue infections are mostly seen in post monsoon season, preventive measures should in full swing at the very onset of the monsoons.

ACKNOWLEDGEMENT

The authors wish to express their sincere gratitude to Department of Pharmacy Practice, Creative Educational Society's College of Pharmacy, N.H. 4, Chinnatekur, Kurnool, Andhra Pradesh, India for providing necessary facilities to carry out this case studies work.

CONFLICT OF INTEREST

We declare that we have no conflict of interest.

BIBLIOGRAPHY

1. Mohsin Bin Mushtaq, Mehmood I Qadri and Aaliya Rashid. Concurrent infection with dengue and malaria: An unusual presentation, *case reports in medicine*, 2013, article ID 520181, 2013, 2. doi: 10.1155/2013/520181.
2. Uneke C J. Concurrent malaria and typhoid fever in the tropics: the diagnostic challenges and public health implications, *J Vector borne dis*, 45(2), 2008, 133-142.
3. Charrel R N, Brouqui P, Foucault C, De Lamballerie X. Concurrent dengue and malaria, *Emerg Infect Dis*, 11(7), 2005, 1153-1154.
4. Mushtaq M B, Qadri M I, Rashid A. Concurrent infection with dengue and malaria: An unusual presentation, *Case rep med*, 2013, 2013:520181.
5. Wiwanitkit V. Concurrent malaria and dengue infection: A brief summary and comment, *Asian Pac J Trop Biomed*, 1(4), 2011, 326-327.
6. Gubler D J. The global threat of emergent/re-emergent vector borne diseases, Understanding the environmental human health and ecological connections Washington DC: *The national academies press*, 2008, 43-46.
7. Alirol E, Getaz L, Stoll B, Chappuis F, Loutan L. Urbanisation and infectious diseases in a globalised world, *Lancet Infect Dis*, 11(2), 2011, 131-141.
8. Washington Winn, Stephan Allen, William Janda *et al.* Koneman's colour atlas and textbook of diagnostic microbiology, *LWW*, 6th Edition, 2005, 1294.
9. Butter T. Typhoid fever, In: Wyngarden J B, Smith L H, Bennet J C. Cecil textbook of medicine, *Philadelphia, USA: W.B. Saunders Co*, 10(3), 19th Edition, 1992, 1690-1692.
10. Chuansumrit A, Chaiyaratana W. Hemostatic derangement in dengue hemorrhagic fever, *Thromb Res*, 133(1), 2014, 10-6.

11. Dan L. Longo, Dennis L. Kasper, Larry Jameson J, Anthony S. Fauci, Stephen L. Hauser, Joseph Loscalzo. Editor. Harrison's principles of internal medicine, *New York, McGraw Hill, Malaria*, 18th Edition, Chapter 210, 2008.

Please cite this article in press as: Shaik Ali Basha *et al.* Triple infection of dengue, malaria and typhoid: a rare case report in pediatrics, *Asian Journal of Research in Pharmaceutical Sciences and Biotechnology*, 5(2), 2017, 38-41.